(J I D P T S)
ISSN(O):2581-6934

MORPHOLOGICAL AND MORPHOMETRIC CHANGES OF THE STOMACH LAYER OF ONE MONTHLY WHITE RATS

Shukhrat Zhumaevich Teshaev[1], Dilshod Karimovich Khudoiberdiev[2], Khodzhaeva Dilrukh Ilkhomovna[3], Navruzov Rustam Rashidovich[4]

[1,2,3,4] Bukhara State Medical Institute named after Abu Ali ibn Sino, Republic of Uzbekistan, Bukhara, E-mail:

ANNOTATION: The study was carried out on 16 30-day-old white random bred rats. Animals were withdrawn from the experiment at 30 days of age by instant decapitation of animals under ether anesthesia. After opening the abdominal cavity, the microscopic changes in the stomach were examined. Using a caliper, the anatomical parameters of the extracted stomach were measured. The stomach was fixed in 10% formalin solution and embedded in paraffin according to generally accepted rules. Then, histological sections with a thickness of 6-7 μm were prepared, which were stained with hematoxylin and eosin. Morphometric studies of the stomach tissue were carried out under a Leyka microscope. In 1-month-old rats, the total thickness of the stomach wall in its cardial part and in the place of transition to the duodenum remained unchanged, but a well-developed mucous and submucosa of the wall was revealed.

Keywords: rat, stomach, morphology, mucous membrane.

INTRODUCTION

The digestive system plays an important role in the body's connection with the environment. The mucous membrane of the digestive organs is affected by a wide variety of substances that make up the food, and it becomes clear that it is no coincidence that the mucous membrane and sub mucosa have their own lymphoid formations, which are organs of immunogenesis [Pozharisskaya ETC. et al. 2016, Proshina L.G. et al. 2004]. The mucous membrane of the organs of the digestive system, on the one hand, is a barrier structure that prevents the penetration of various agents of the external world into the body, and on the other hand, it participates in metabolic processes between the external and internal environment of the body. Due to its proximity to micro biota and direct contact with food, it is constantly exposed to both "normal" and potentially dangerous antigens [Chava S.V. 2004]. In terms of prevalence and disability, gastrointestinal lesions occupy one of the first places in the overall structure of morbidity among the population. In epidemiological studies carried out using gastro copy and with a morphological assessment of the state of the gastric mucosa, it was shown that about half of the population suffers from chronic gastritis [Siurala M. 1999]. Immunocompetent tissues of the digestive tract are called lymphoid tissue. As a result of the recirculation of lymphocytes and cloning, the immune response covers all mucous membranes of the gastrointestinal tract [Royt A. et al 2000]. In gastroenterological pathology caused by a dysfunction of the immune system of the gastrointestinal tract, the importance of morphology and biopsy has increased as an objective indicator of diagnosis and treatment [Kuznetsova T.A. et al 2007]. Of the physical factors, the most detailed study is the effect of ionizing radiation on the digestive system. As is known, in chronic radiation sickness, mainly functional disorders of the nervous and cardiovascular systems are observed. In the reaction of the gastrointestinal tract to radiation, a gradual decrease in the secretary function of the gastric glands is characteristic. These deviations are well compensated and may not be accompanied by subjective disorders for a long time. The choice of the stomach for research is dictated by the fact that most people suffer from various diseases of this organ; gastritis and gastric

ulcer make up the predominant percentage among patients, and at the same time information on the fine structure of the lymphoid structures of the stomach walls in the scientific literature is extremely insufficient [Korolev Yu.N. 1998, Siurala M. 1999].

The purpose of the research.

The aim of the research is to study the morph metric parameters of the stomachs of white rats with chronic radiation sickness and correction with the ASD-2 biostimulator in postnatal ontogenesis.

MATERIALS AND METHODS

The studies were carried out on 16 one-month-old white rats. On the 30th day of development, the abdominal cavity was decapitated under ether anesthesia and the macroanatomy, sclerotopy, and syntopy of the stomach were studied. After macroanatomy, the stomach was isolated for further study. The process of experiments on laboratory animals was carried out in accordance with the Declaration of the International Medical Association, adopted in Helsinki in 1964 and completed in 1975, 1983, 1989, 1996, 2000, 2002, 2004, 2008, 2013. The isolated stomach was fixed in solution and poured into paraffin. Then, incisions with a size of 6–7 µm were prepared and stained using the hematoxylin-eosin and Van Gieson methods. Histological preparations were examined under 10, 20, 40 lenses of a light microscope and the necessary areas were photographed. Mathematical processing was performed in Excel 7.0 and typical error rates were determined.

RESULTS

In 30-day-old white rats, the esophagus of the gastric mucosa has three rows of cells that form a stratified keratinized epithelium. The cells of the basal row are oval in shape, smaller in size than the cells of the middle and upper layers, and the nucleus is located in the center of the cell. The cells of the middle and upper rows, in contrast to the cells of the basal row, have eccentric nuclei, with a greater number of cells located on the lateral side. In the apical part of the cell, there are secretary granules. The cells of the upper row are covered with a cuticle (Fig. 1).

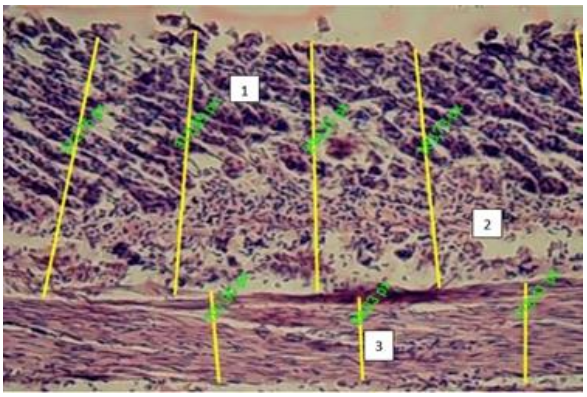

Fig .1. The structure of the esophageal stomach of 30-day-old white rats. 1st mucous layer, 2nd sub mucosal layer, 3rd muscle layer. Coloring: H-E. SW: about 10, ob. 20. Coloring: HE(hematoxylin-eosin). SW: eyepiece 10, ob. 20.

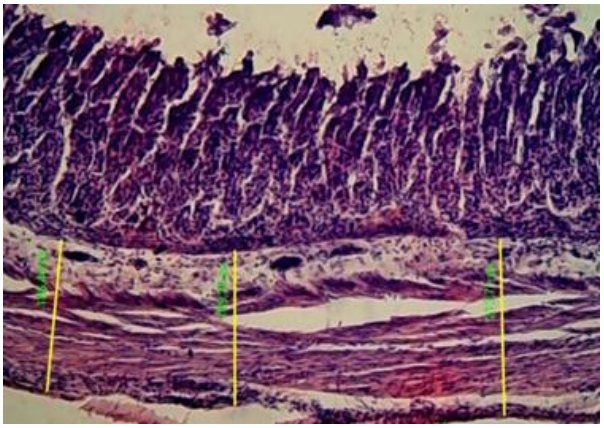

Fig 2. The structure of the 12-fold stomach of 30-day-old white rats. 1st mucous layer, second submucosal layer, third muscle layer. Coloring: H-E. SW: about 10, ob. 20. Coloring: HE(hematoxylin-eosin). SW: eyepiece 10, ob. 20.

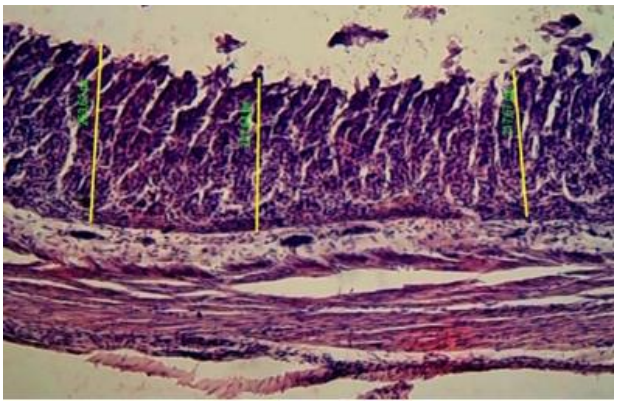

Fig 3. The structure of the 12-fold stomach of 30-day-old white rats. 1st mucous layer, second submucosal layer, third muscle layer. Coloring: H-E. SW: about 10, ob. 20. Coloring: HE(hematoxylin-eosin). SW: eyepiece 10, ob. 20. The stomach of white rats was examined in two parts: the esophageal part of

ISSN:-2581-6934 |Available at :www.jidps.com | pp :(7-10)

the stomach and the 12-duodenal part of the stomach or the intestinal part of the stomach. The thickness of the stomach wall and the layers that make up the wall of thirty-day-old white rats are shown in the table below.

Table 1

Stomach layer thickness and layers in 30-day-old white rats

Stomach layer components	Esophageal stomach	12-finger part of the stomach
Total gastric layer thickness	393,3-522,1 452,9±5,2	278,9-570,3 436,3±6,2*
Miscellaneous layer	186,4-258,5 217,1±2,8	65,5-130,6 104,8±3,1*
Circulating muscle layer	31,0-103,0 78,7±1,5	31,0-85,8 50,3±1,3*
Longitudinal muscle layer	45,6-224,2 138,4±1,3	32,8-78,3 54,5±2,8*
Mucosal thickness	206,9-263,6 235,4±1,2	212,9-439,7 331,6±3,5*
Base of the mucous membrane	20,5-90,2 53,3±1,2	12,3-69,7 22,5±1,2

* - The difference in the degree of confidence with the sign was obtained for the esophageal part of the stomach ($R \geq 0.05$).

As can be seen from the above table, the total thickness of the stomach layer is practically indistinguishable from the thickness of the outlet (intestinal), but the muscle layer is -2.1 times thinner, the mucous layer is -1.4 times thicker; the thickness of the submucosa is -2. 4 times thinner. In the mucous membrane of the stomach there are special glands that have a simple, branched character. The glandular apparatus is mainly located in the lesser and greater curvature and pyloric part of the stomach. The glands are located along the greater curvature. The glands are located on a special lamina of the mucous membrane and are separated from each other by a thin membrane of connective tissue. In the glands, the main part (bottom and body) and branch pipes are distinguished. The lower diameter of the glands located in the zone of the greater curvature of the stomach is from 18.6 to 23.1 microns, the density is from 6 to 9, the density of the glands of the lesser curvature is from 10 to 13, the lower diameter of the glands in the pyloric canal is from 22.2 up to 23.9 microns, its density varies from 10 to 13. The base and body of the glands are made up of head cells and parietal cells, and the neck area is made up of parietal cells and mucus-producing cells. Stem cells are round in shape, and the nuclei are located in the center of the cell. The main cells are smaller than the parietal cells. Parietal cells are often oval in shape with 1 or 2 nuclei in the center. The mucus-producing cells are elongated and retain an oval or triangular nucleus in the center of the cell. The submucosa consists of fibrous connective tissue, collagen fibers located in the esophageal part of the stomach are thinner and thinner, and in the intestinal tract of the stomach they are densely located, forming various bundles. The elastic fibers are very weak and sparse, longitudinally oriented. They appear mainly around arterioles at the base of the submucosa. The reticular fibers form a small chain network. The network of reticular fibers in the intestinal part of the stomach is 2-3 times thicker than in the esophagus. The muscular layer of the stomach consists of circular and longitudinal layers, and the longitudinal layer is thicker than the circular layer, especially more than 2 times thicker at the transition to the intestinal tract of the stomach. Outside, the stomach is lined with a serious membrane, and flat mesothelial cells are located in one layer and at the base of the connective tissue. The thickness of the outer shell of the stomach varies slightly along the wall. This change is from 4.1 microns to 20.5 microns. The vascular system of the stomach layer, they consist of arterioles, capillaries and venues. The wall of the arteriole consists of three membranes: the inner membrane is formed by rounded endothelial cells located at a short distance from each other. The middle muscle layer is characterized by a number of smooth muscle cells. The outer shell consists of a thin fibrous tissue. The capillary layer is represented only by endothelial cells. The venue layer is composed of larger endothelial cells.

CONCLUSION

Thus, our study showed that in one-month-old white rats, the total thickness of the stomach layer in the tibial and pyloric parts remained practically unchanged, but the mucous and sub mucosal bases were well developed, and were sufficiently developed for the digestion process.

LIST OF REFERENCES

[1] Zhuraeva G.B. The activity of pathomorphological changes in the intestinal lymphoid tissue under the influence of acute intestinal infections // Yakutsk Medical Journal 2015 №2 (50) p 63-67.

[2] Zhuraeva, G.B., Saidov, A.A., & Israilov, R.I. (2015). The dependence of morphological and morphometric

changes in the mucous membrane in acute intestinal infection on the type of pathogen // Youth Innovative Bulletin, 4 (1), 193-195.

[3] Sapin M.R. The lymphatic system and its role in immune processes // Morphology, 2012, v. 141, no. 3, p. 139.

[4] Safonova M.A. Hygienic assessment of the impact of technogenic environmental factors on the development of chronic gastroduodenitis in children (on the example of the Perm Territory): / Avtoref.dis.kan.nauk Perm, 2009; 24.

[5] Teshaev Sh. Zh., Khasanova D.A. Macroscopic structure of Peyer's patches of the rat small intestine and changes in the intestine under the influence of chronic irradiation // Operative surgery and clinical anatomy (Pirogov scientific journal) 2020, Volume 4, No. 1, pp. 41-45.

[6] Teshaev Sh. Zh., Khasanova D.A. Comparative characteristics of the morphological parameters of the lymphoid structures of the small intestine of rats before and after exposure to the antiseptic-stimulant Dorogov fraction 2 against the background of chronic radiation sickness // Operative surgery and clinical anatomy (Pirogov scientific journal) 2019, Volume 3, No. 2, P.19-24.

[7] Teshaev Sh.Zh., Khudoiberdiev D.K., Teshaeva D.Sh. The impact of exogenous and endogenous factors on the stomach wall // Problems of Biology and Medicine. 2018, No. 4 (104). S. 212-214.,

[8] D.K. Khudoiberdiev The influence of environmental factors on the morphology of the stomach // Problems of Biology and Medicine. 2019, no. 3 (111). S. 295-297.

[9] Chava S.V. Reactive changes in immune structures in the wall of the small intestine // Morphological statements, 2004, No. 1-2, p. 114-115.

[10] Shamirzaev N.Kh., Teshaev Sh.Zh., Khasanova D.A. Ingichka ichak lymphoid tuzilmalaring morphometrics hususiyatlari va surunkali nur kasalligida ASD 2 fraction ta'siridagi ўzgarishlari // Uzbekistan medical journals. - No. 2.- 2019. B. 106-110.

[11] Teshaev Sh.J., Khasanova D.A. Topografic-anatomical features of lymphoid structures of the small intestine of rats in norm and against the background of chronic radiation diseases // European science review Vienna, Austria No. 9-10 2018, Volume 1 Medical science P. 197-198.

[12] Hodorova I., Khasanova D.A., Teshaev Sh.J. Macroanatomy of Payer's patches of rat's small intestine under the influence of antiseptic-stimulator Dorogov faction 2 on the background of chronic radiation sickness // New Day in Medicine– 2020, 2 (1), 21

[13] Siurala M., Voris K. Gastritis - In: Scientific Foundations of Gastroenterology, edited by W. Sircus and A. N. Smith, 357-369, London, William Heinemann Medical Books Ltd., 1999.

ISSN:-2581-6934 |Available at :www.jidps.com | pp :(7-10)